

Research Journal of Pharmaceutical, Biological and Chemical Sciences

Association between Subclinical Hypothyroidism and Severe Diabetic Retinopathy in Type 2 Diabetic Patients.

Nidhi.Takkar¹, Jai Prakash Takkar², Navin Patil³, Karthik Rao N^{4*},
Raghavendra Rao⁴, Shubha Sheshadri⁵, Avinash A³, and Anusha Venkatesh⁶.

¹Consultant Physician and Diabetologist, PMC American Hospital, Kota, Rajasthan, India.

²Senior Resident, Department of Medicine, New Medical College, Kota, Rajasthan, India.

³Department of Pharmacology, KMC Manipal (Manipal University), Manipal, Karnataka, India.

⁴Assistant Professor, Department of Medicine, KMC Manipal (Manipal University), Manipal, Karnataka, India.

⁵Professor, Department of Medicine, KMC Manipal (Manipal University), Manipal, Karnataka, India.

⁶Undergraduate, KMC Manipal (Manipal University), Manipal, Karnataka, India.

ABSTRACT

This study was undertaken to assess the less-known association between subclinical hypothyroidism and severity of diabetic retinopathy in patients with type 2 diabetes mellitus. Among 35 diabetic patients who were subclinically hypothyroid, 20 (57.1%) had retinopathy as compared to 21 patients (30%) in the euthyroid group, which was significant ($p=0.011$). SCH was also significantly associated with severe diabetic retinopathy ($p<0.001$). Also, there were differences in TSH levels in different stages of retinopathy. As the level of TSH was increasing, the severity of retinopathy was also increasing. There was a clear association between the thyroid status and the diabetic retinopathy status of patients with type 2 diabetes mellitus.

Keywords: Thyroid, Diabetes mellitus, Retina

**Corresponding author*

INTRODUCTION

Diabetic retinopathy, which is a severe microvascular complication of diabetes mellitus, is a leading cause of visual impairment. Subclinical hypothyroidism (SCH) is associated with type 2 diabetes mellitus, with a prevalence of 2.2%-17% [1,2]. Thyroid hormone has an important role in the development of retina [3]. Hypothyroidism has been known to cause preretinal neovascularisation in animal studies [4,5]. Experimental studies have also shown that thyroid hormone administration can normalize retinal vascular density [6]. Diabetic vascular complications can also be explained by dyslipidemia in subclinical hypothyroidism [7-9]. Statin therapy has shown to reduce the development as well as severity of diabetic retinopathy [10]. SCH is also responsible for endothelial dysfunction, which plays a pivotal role in diabetic microangiopathy [11].

Owing to the increased public health importance of diabetic retinopathy, and as a part of investigative research into the less known associations of diabetic retinopathy, we undertook this study. We investigated the association between SCH and retinopathy in type 2 diabetes mellitus patients.

Aim

To investigate the association between subclinical hypothyroidism and severe diabetic retinopathy in patients with type 2 diabetes mellitus.

MATERIALS AND METHODS

Study Design

The study was designed to be a cross-sectional observational study.

Selection Criteria

Inclusion Criteria

Patient with normal T3, T4 and increased TSH ($>4.5\mu\text{IU/ml}$) level were diagnosed with SCH. All SCH type 2 diabetic patients (n=35) and 70 cases of euthyroid type 2 diabetic patients who were randomly selected from the rest of the 437 subjects were included in the further investigation.

Exclusion Criteria

Patients with known thyroid diseases, thyroidectomy, malignancy, pregnancy, hepatitis, cirrhosis, nephrotic syndrome and any acute intercurrent illness were excluded.

METHODOLOGY

A total of 437 (type 2 diabetic) patients were screened for thyroid function. Informed consent was taken from all the patients, and the study protocol was approved by the institutional ethic committee.

Patients underwent a general ophthalmic examination, followed by a dilated fundoscopic examination by an ophthalmologist. If needed, fluorescein angiography was also performed. Retinopathy was assessed using fundus photographs. Photographs were taken in a darkened examination room after dilatation, and graded using Modified Airlie House Classification scheme and the Early Treatment for Diabetic Retinopathy Study severity scale to grade the photographs as follows: no retinopathy (graded 010 or 015), mild non-proliferative diabetic retinopathy (NPDR) (020 or 031), moderate to severe NPDR (041 or 051), or proliferative diabetic retinopathy (PDR) (060, 065, or 070; or evidence of photocoagulation treatment noted outside arcades) [12].

Patients were further divided into 3 groups.

Group I: no retinopathy

Group II: mild-moderate NPDR,

Group III: severe retinopathy (which included severe NPDR and PDR).

RESULTS

Out of 437 type 2 diabetic patients, 35 (8%) had SCH. Base line characteristics of SCH and euthyroid patients (age, sex, diabetes duration, HbA1c, BMI, BP, total cholesterol, triglyceride, LDL, HDL and GFR) showed no significant statistical difference (as depicted in Table 1).

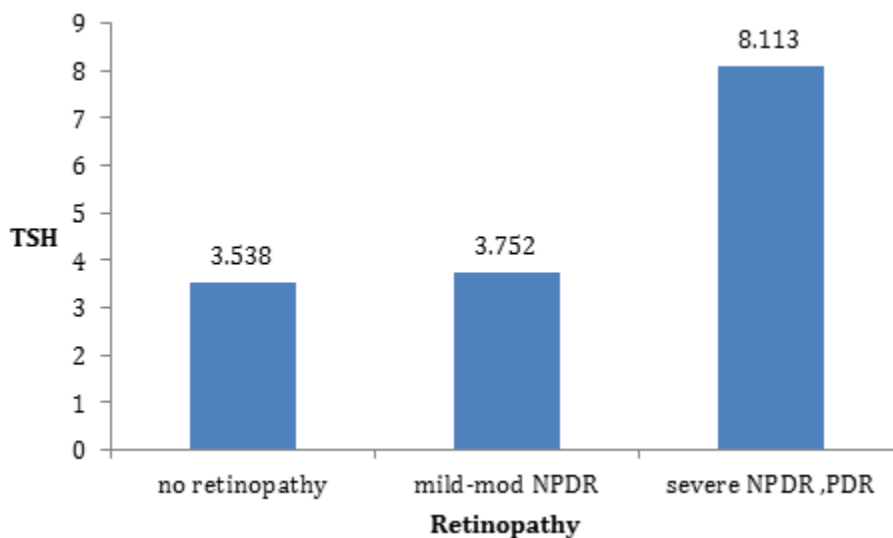
Table 1: Baseline Characteristics

	EUTHYROID	SCH	p value
N	70	35	
AGE(Yrs)	53.54±9.46	52.31±8.37	0.499
GENDER(M/F)	28/42	16/19	0.576 [†]
DURATION	5(2-10)	5(2-15)	0.777 [*]
BMI	27.23±3.58	25.48±4.97	0.062
SYSTOLIC BP	140(130-160)	138(130-150)	0.772 [*]
DIASTOLIC BP	82(80-90)	80(80-90)	0.701 [*]
Total cholesterol	205±43	205±50	0.976
Triglyceride	170(142-230))	189(128-248)	0.698 [*]
LDL	122±37.06	128.9±48.01	0.471
HDL	39(34-43)	36(30-44)	0.289 [*]
Creatinine	0.9(0.7-1)	1(0.7-1.4)	0.084 [*]
GFR	80.73±25.46	68.71±34.39	0.073
HbA1c	8.9±1.99	9.4±2.36	0.264
Severe NPDR and PDR	2(2.9)	11(31.4)	0.011 [‡]
Mild-moderate NPDR	19(27.1)	9(25.7)	
No retinopathy	49(70)	15(42.9)	

Data in Table 1 are expressed as mean ± SD or Median (inter quartile range), unless otherwise indicated. Student t-test; *Mann-Whitney U test; †Fisher exact test; ‡Pearson χ^2 test

Among 35 SCH diabetic patients, 20 (57.1%) had retinopathy as compared to 21 patients (30%) in euthyroid group, which was significant (p=0.011). SCH was also significantly associated with severe diabetic retinopathy (p<0.001).

Figure 1: Comparison of TSH levels



Our study also revealed that there were differences in TSH levels in different stages of retinopathy. As the level of TSH was increasing, the severity of retinopathy was also increasing. Mean TSH in patients having severe retinopathy in both euthyroid and SCH group was 8.113, which was significantly more than the mean TSH (3.752&3.538) in mid - moderate retinopathy patients and no retinopathy patients respectively ($p<0.001$, $p<0.001$). But the difference between TSH of patients with no retinopathy and mild to moderate retinopathy was not statistically significant ($p=0.677$). The values are compared in Figure 1.

DISCUSSION

The pathogenesis of diabetic microangiopathy is multifactorial. Endothelial dysfunction plays an important role in the pathogenesis of microvascular complications [13]. Various vasodilatory and vasoconstrictor substances are produced by the endothelium, which in turn, maintain normal vascular function and integrity [14,15]. Vascular endothelium produces nitric oxide (NO) [16, 17], which is the most important vasodilatory factor, and is derived from the conversion of L-arginine to citrulline through the activity of the enzyme NO synthase [18]. Hyperglycemia can generate oxidative stress, which causes NO breakdown and decreased NO availability [14, 19].

Patients with SCH also have endothelial dysfunction, which is responsible for microangiopathy [11]. Studies also suggest the presence of an early, reversible impairment of endothelium-dependent vasodilatation in SCH patients (possibly because of reduced NO availability), which can only be partly explained by the mild dyslipidemia [20]. With thyroxine supplementation, not only TSH and LDL cholesterol improve, but the maximal vasodilatory response to acetylcholine that indicates endothelial dysfunction also improves [20].

In our study, we found a significant association between SCH and diabetic retinopathy ($p=0.011$). Severe retinopathy (severe NPDR and PDR) was also significantly more in patients with SCH ($p<0.001$). Our findings are supported with the results of Yang et al. from China, who also found sight-threatening diabetic retinopathy more in SCH patients [21]. Further, Kim et al. from Korea also found a significant association between subclinical hypothyroidism and severe retinopathy [22]. There was a much more severe retinopathy in SCH diabetic patients as SCH can worsen pre-existing diabetic retinopathy.

There is evidence that there is a relationship between maximal endothelial dysfunction and serum TSH levels [20]. In our study, the mean TSH level was increasing with the grade of retinopathy. The mean TSH level was significantly higher in severe retinopathy patients than in patients with mild-moderate retinopathy and no retinopathy ($p<0.001$). Khodeir et al. from Egypt also found that type 2 diabetic patients with subclinical hypothyroidism had an association between TSH level and the grade of diabetic retinopathy [23]. Similarly Gaung et al. from china reported that patients with PDR had higher levels of TSH [24].

Limitations

Our study was a cross-sectional study and could not determine causal relationships. Whether thyroxine supplementation can prevent or treat diabetic retinopathy is yet to be proven. Prospective controlled studies need to be undertaken in these directions in the future.

CONCLUSION

To conclude, our study has shown significant association between the severity of retinopathy and thyroid hormone levels in patients with type 2 diabetes mellitus, as evidenced from a few studies in the past. Hence, correcting subclinical hypothyroidism might help in prevention or treatment of diabetic retinopathy as well. However, further extensive studies are required to ascertain the same.

REFERENCES

- [1] Perros P, McCrimmon RJ, Shaw G, Mathieu C, Frier BM. Diabet Med 1995;12:622-7.
- [2] Smitson J. Diabet Med 1998;5:148-50.
- [3] Sevilla Romero E, Munoz A, Pinazo Duran MD. Ophthalmic Res 2002;34:181–91.
- [4] Dorey CK, Aouididi S, Reynaud X, Dvorak HF, Brown LF. Arch Ophthalmol 1996;114:1210-7.

- [5] Mookadam M, Lese DA, Fautsch MP, Lanier WL, Holmes JM. Invest. Ophthalmol Vis Sci 2004;45:4145-50.
- [6] Mutapcic L, Wren SM, Lske DA, Fautsch MP, Holmes JM. Curr Eye Res 2005;30:1035-40.
- [7] Chew EY, Klein ML, Ferris LF, Remaley NA, Murphy RP, Chantry K, Hooqwerf BJ, Miller D. Arch Ophthalmol 1996;114:1079-84.
- [8] Klein BE, Moss SE, Klein R, Surawicz TS. Ophthalmol 1991;98:1261-5.
- [9] Vierhapper H, Nardi A, Grosser P, Raber W, Gessl A. Thyroid 2000;10:981-4.
- [10] Gordon B, Chang S, Kavanagh M, Berrocal M, Yannuzzi L, Robertson C, Drexler A. Am J Ophthalmol 1991;112: 385-91.
- [11] Cikim AS, Ofiaz H, Ozbey N, Cikim K, Umman S, Meric M, Sencer E, Molvalilar S. Thyroid 2004;14:605-9.
- [12] Ophthalmol 1991;98(5 suppl):786-806.
- [13] Kirpichnikov D, Sowers JR. Trends Endocrinol Metab 2002;12:225-30.
- [14] Luscher TF, Vanhoutte PM: The endothelium: modulator of cardiovascular function. Boca Raton, FL: CRC Press1990; 1–215.
- [15] Furchgott RF, Zawadzky JV Nature 1980; 288:373–6.
- [16] Palmer RMJ, Ferrige AG, Moncada S. Nature 1987;327: 524–6.
- [17] Palmer RMJ, Ashton DS, Moncada S. Nature 1988; 333:664–6.
- [18] Brecht DS, Hwang PM, Glatt CE, Lowenstein C, Reed RR, Snyder SH. Nature 1991; 351:714-8.
- [19] Taddei S, Virdis A, Ghiadoni L, Magagna A, Salvetti A. Circulation 1998; 97:2222–9.
- [20] Taddei S, Caraccio N, Virdis A, Dardano A, Versari D, Ghiadoni L, Salvetti A, Ferrannini E, Monzani F. J Clin Endocrinol Metab 2003;88:3731-7.
- [21] Yang JK, Liu W, Shi J, Li YB. Diabetes Care 2010;33:1018-20.
- [22] Bo- Yeon Kim, Chul-Hee Kim, Chan-Hee Jung, Ji-Oh Mok, Kyo-II Suh, Sung-Koo Kang. Endocrine 2011;58(12):1065-70.
- [23] Khodeir SA, Abd El, Raouf YM, Farouk G, Allam WA. J Am Sci 2012;8(1):525-30.
- [24] Guang-Ran Yang, Jin-Kui Yang, Lin Yang, Yan-Hua An, Jing-Kui LuTohoku J Exp Med 2010;222:303-10